

RECEIVED
AUG 27 2008

DOCKET NO. 2008-82

IN THE MATTER OF § TEXAS BOARD OF VETERINARY MEDICAL EXAMINERS
THE LICENSE OF § VETERINARY
PATRICK JARRETT, D.V.M. § MEDICAL EXAMINERS

AGREED ORDER

On this the 16 th day of October, 2008, came to be considered by the Texas Board of Veterinary Medical Examiners ("Board") the matter of the license of Patrick Jarrett, D.V.M. ("Respondent"). Pursuant to Section 801.408, Texas Occupations Code and Board Rule 575.27, an informal conference was held on August 18, 2008. The Respondent appeared and represented himself. The Board was represented at the conference by the Board's Enforcement Committee.

Respondent, without admitting the truth of the findings and conclusions set out in this Agreed Order, wishes to waive a formal adjudicative hearing and thereby informally dispose of the issues without a formal adjudication. Respondent agrees to comply with the terms and conditions set forth in this Order. In waiving an adjudicative hearing, Respondent acknowledges their understanding of the alleged violations and the adequacy and sufficiency of the notice provided to them.

Upon the recommendation of the Enforcement Committee and with Respondent's consent, the Board makes the following Findings of Fact and Conclusions of Law and enters this Agreed Order as set forth below.

Findings of Fact

1. On May 26, 2006, Glenda Campbell of Weatherford, Texas, presented "Conner", a three-year-old male Domestic Shorthair cat to Patrick Jarrett, D.V.M., Weatherford, Texas, of Parker County Veterinary Clinic (PCVC) for constipation and vomiting.
2. Dr. Jarrett examined "Conner" and performed a blood panel. The blood panel results were normal. Dr. Jarrett took "Conner" from the examination room to a treatment area to administer mineral oil to pass any hair the cat may have ingested. Without sedation, Dr. Jarrett placed a feeding tube into "Conner" and administered 10 cc of mineral oil followed by 10 cc of water. Dr. Jarrett returned shortly thereafter with "Conner." "Conner" appeared to experience difficulty with breathing. According to Ms. Campbell, "Conner" had an audible grunt when he breathed. Ms. Campbell pointed this out to Dr. Jarrett, but Dr. Jarrett stated the audible grunt might have been from reflux. Dr. Jarrett did not reexamine "Conner." Ms. Campbell took "Conner" home but he was breathing rapidly. Ms. Campbell called back to Dr. Jarrett's office and informed them

of the cat's condition. Dr. Jarrett again reiterated that the cat's condition was most likely mineral oil reflux, but offered to examine "Conner."

3. Instead, that evening, Ms. Campbell presented "Conner" to VCA Fort Worth Animal Medical Center (VCA) in Fort Worth, Texas. Dr. Toby Rouquette examined "Conner" and found him in acute respiratory distress. After discussing the clinical signs and history with Ms. Campbell, Dr. Rouquette explained to Ms. Campbell he was concerned about aspiration pneumonia. Dr. Rouquette's radiographs showed no significant abnormalities, but Dr. Rouquette explained that changes associated with aspiration could take several days to appear. Dr. Rouquette started "Conner" on IV Ampicillin, IV Zithromax, oxygen supplementation and nebulization treatment. Over the next several days "Conner's" condition did not improve and he was uninterested in eating. Dr. Leslie MacLean, with VCA, took over the treatment of "Conner" on May 30th. "Conner" was still unable to be removed from oxygen. When "Conner" was removed from oxygen he would become tachypnic and start open mouth breathing. "Conner" was treated but was not significantly improving. On June 1st, Dr. Jennifer Parsley, also with VCA, took chest radiographs of "Conner". The radiographs revealed a progression of pneumonia with increased lung consolidation. These results were discussed with Ms. Campbell and Ms. Campbell had "Conner" euthanized that same day.

4. Dr. Jarrett asked for a board certified radiologist to review the radiographs in this matter. On March 14, 2008, Ronald Green, D.V.M., Diplomate A.C.V.R. of the Animal Radiology Clinic in Dallas, Texas conducted a radiographic interpretation of four sets of radiographs taken on May 26, 27, 28 and June 1, 2007. The three radiographs from May 26, 2007 showed diffuse bronchointerstitial markings observed throughout the lungs. There was increased soft tissue density noted in the cranial mediastinum near the level of the thoracic inlet. The lungs were over expanded and free gas was present in the pleural space. No obvious alveolar infiltrates or "air bronchograms" were present. Radiographs of the abdomen revealed the stomach dilated with air. The radiographic findings were compatible with a diagnosis of a pneumothorax secondary to perforation of the esophagus and/or trachea. Fluid density was seen in the cranial mediastinum, which may have represented blood or possibly injected fluid. The three radiographs from May 27, 2007 revealed that previously described pneumothorax had progressed into a pneumomediastinum and pneumoperitoneum. Free gas was present in the mediastinum, pleural space and retroperitoneal space. "Classic" radiographic signs of a pneumomediastinum were present. Those signs included visualization of the serosal margins of the esophagus, visualization of the walls of the trachea, visualization of the dorsal surfaces of the cranial vena cava, visualization of the left subclavian artery and brachiocephalic artery. Reflection of some of the pleura was noted. No signs of alveolar infiltration or air bronchogram were observed. Radiographs of the abdomen revealed free gas in the retroperitoneal space. The radiographic findings were compatible with perforation of the esophagus or trachea in the cranial mediastinum and dissection of gas through the mediastinum and into the retroperitoneal space. The two radiographs from May 28, 2007 showed mild improvement of the previously described pneumothorax and pneumomediastinum. The radiographs showed generalized alveolar

infiltration of the lungs. Some peribronchial cuffing was noted. Partial atelectasis of both caudal lung lobes and the right middle lung lobe was noted. The radiographs revealed pneumothorax, pneumomediastinum, and partial atelectasis of the right middle lung lobe and both caudal lung lobes. Differential diagnosis would include early diffuse pulmonary edema and early diffuse bronchopneumonia. The three radiographs from June 1, 2007 were reviewed. The radiographs of the thorax showed improvement of the previously described pneumothorax and pneumomediastinum. There was very little free gas present in the mediastinum. The trachea narrows or is strictured just cranial to the thoracic inlet. Diffuse peribronchial and alveolar infiltrates are present. "Conner" now has diffuse alveolar infiltrates. Differential diagnosis would include diffuse pulmonary edema and a narrowed trachea and pulmonary infection (bronchopneumonia). Dr. Green provided new evidence on March 14, 2008 by sending in a clarification of his previous findings. Dr. Green stated: the radiographs showed: 1. Free gas in the pleural space and increased soft tissue density in the cranial mediastinum---5/25/07; 2. Free gas in the mediastinum and pleural space---5/26/07; 3. Free gas in the mediastinum, pleural space, and peritoneal space---5/27/08; 4. Complications of alveolar infiltrates were seen throughout the lungs---6/1/07. In my opinion, a puncture or a tear in the trachea or esophagus in the cranial mediastinum occurred on/or before 5/25 which allowed gas to infiltrate into the mediastinum. This free gas created a pneumomediastinum, pneumothorax and subsequently a pneumoperitoneum. Pulmonary complications (pulmonary edema/bronchopneumonia) occurred on 6-1."

5. Dr. Jarrett's failure to reexamine "Conner" on May 26, 2008 when Ms. Campbell pointed out the audible grunting by "Conner" does not represent the same degree of humane care, skill, and diligence in treating patients as is ordinarily used in the same or similar circumstances by average members of the veterinary medical profession in good standing in Weatherford, Texas or similar communities. The failure to reexamine "Conner" led to unnecessary pain and suffering for "Conner."

Conclusions of Law

1. Respondent is required to comply with the provisions of the Veterinary Licensing Act, Chapter 801, Texas Occupations Code, and with the Board's Rules.

2. Based on Findings of Fact 1 through 5, Respondent has violated Rule 573.22, PROFESSIONAL STANDARD OF HUMANE TREATMENT, of the Board's Rules of Professional Conduct, which requires veterinarians to exercise the same degree of humane care, skill and diligence in treating patients as is ordinarily used in the same or similar circumstances by average members of the veterinary medical profession in good standing in the locality or community in which they practice, or in similar communities.

3. Based on Finding of Fact 5 and Conclusions of Law 1 and 2, Respondent has violated Section 801.402 (6) of the Veterinary Licensing Act, Texas Occupations Code, and is subject to disciplinary action by the Board:

801.402. GENERAL GROUNDS FOR LICENSE DENIAL OR DISCIPLINARY ACTION. A person is subject to denial of a license or to disciplinary action under Section 801.401 if the person:

(6) engages in practices or conduct that violates the board's rules of professional conduct.

4. Based on Conclusions of Law 1 through 3, Respondent is subject to disciplinary action under Section 801.401 of the Veterinary Licensing Act, Texas Occupations Code:

801.401. DISCIPLINARY POWERS OF BOARD. (a) If an applicant or license holder is subject to denial of a license or to disciplinary action under Section 801.402, the Board may:

- (1) refuse to examine an applicant or to issue or renew a license;
- (2) revoke or suspend a license;
- (3) place on probation a license holder or person whose license has been suspended;
- (4) reprimand a license holder; or
- (5) impose an administrative penalty.

NOW, THEREFORE, THE BOARD AND RESPONDENT AGREE AS FOLLOWS:

Based on the above Findings of Fact and Conclusions of Law, the Board ORDERS that Patrick Jarrett, D.V.M., be INFORMALLY REPRIMANDED.

The Board further ORDERS that:

1. Respondent shall abide by the Rules of Professional Conduct, the Texas Veterinary Licensing Act, and the laws of the State of Texas and the United States.
2. Respondent shall cooperate with the Board's attorneys, investigators, compliance officers and other employees and agents investigating Respondent's compliance with this Order.
3. Failure by Respondent to comply with the terms of this Agreed Order or with any other provisions of the Licensing Act or the Board Rules, may result in further disciplinary action.

Respondent, by signing this Agreed Order, acknowledges their understanding of the Agreed Order, the notice, and Findings of Fact and Conclusions of Law herein set forth herein, and agrees that they will satisfactorily comply with the mandates of the Agreed Order in a timely manner or be subject to appropriate disciplinary action by the Board.


Respondent, by signing this Agreed Order, waives their right to a formal hearing and any right to seek judicial review of this Agreed Order. Respondent acknowledges that they had the right to be represented by legal counsel in this matter.

RESPONDENT WAIVES ANY FURTHER HEARINGS OR APPEALS TO THE BOARD OR TO ANY COURT IN REGARD TO ALL TERMS AND CONDITIONS OF THIS AGREED ORDER. NOTHING IN THIS ORDER SHALL BE DEEMED A WAIVER OF RESPONDENT'S RIGHTS UNDER STATUTE OR UNDER THE UNITED STATES OR TEXAS CONSTITUTIONS TO APPEAL AN ORDER OR ACTION OF THE BOARD SUBSEQUENT TO THIS AGREED ORDER EXCEPT AS RESPONDENT MAY HAVE OTHERWISE AGREED TO HEREIN. RESPONDENT AGREES THAT THIS IS A FINAL ORDER.

The effective date of this Agreed Order shall be the date it is adopted by the Board.

I, **PATRICK JARRETT, D.V.M.**, HAVE READ AND UNDERSTAND THE FOREGOING AGREED ORDER. I UNDERSTAND BY SIGNING IT, I WAIVE CERTAIN RIGHTS. I SIGN IT VOLUNTARILY. I UNDERSTAND THAT THIS ORDER CONTAINS THE ENTIRE AGREEMENT AND THERE IS NO OTHER AGREEMENT OF ANY KIND, VERBAL, WRITTEN OR OTHERWISE.

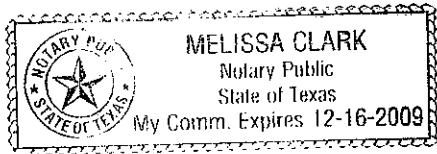

Patrick Jarrett, D.V.M.


Date

STATE OF TEXAS §
COUNTY OF Foster §

BEFORE ME, on this day, personally appeared PATRICK JARRETT, D.V.M., known to me as the person whose name is subscribed to the foregoing document, and acknowledged to me that he executed the same for the purposes stated therein.

Given under the hand and seal of office this 22nd day of August, 2008.



Melissa Clark
Notary Public

SIGNED AND ENTERED by the TEXAS BOARD OF VETERINARY MEDICAL EXAMINERS on this the 16 Day of OCT., 2008.

Bud E. Alldredge, Jr.
Bud E. Alldredge, Jr., D.V.M., President